

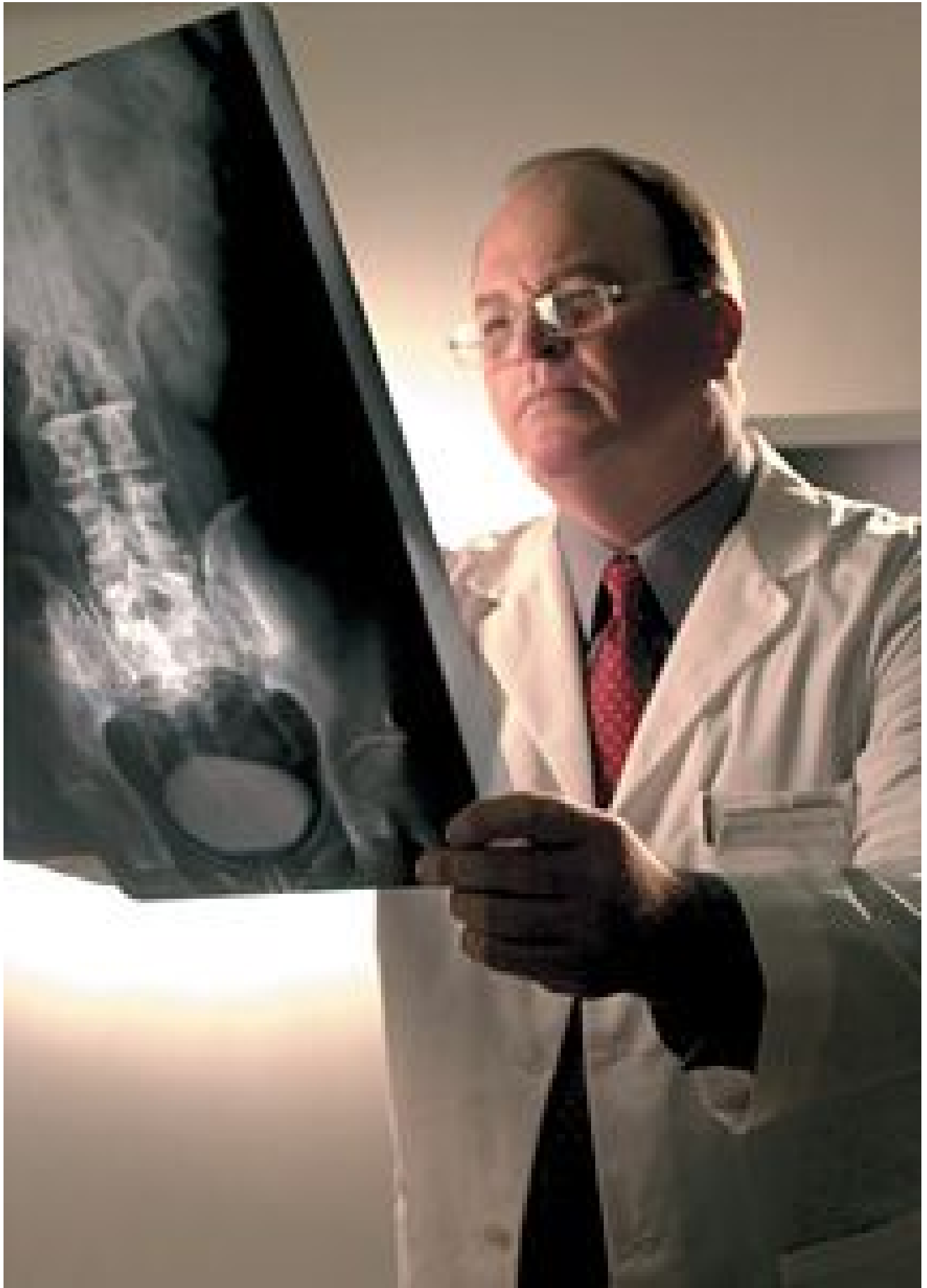
SCuBA: A Useful Mnemonic for Reading Skeletal X-Rays

K. Jeffrey Miller, DC, MBA

When I first studied [radiology](#) in chiropractic college, a mnemonic for reading skeletal radiographs was offered to assist students in establishing an orderly method for reading film. The mnemonic ABC'S represents Alignment, Bone, Cartilage and Soft tissues. I found the mnemonic very useful; I used it in college and during my first few years of practice. It definitely helped me remember to look at each of these diagnostic factors methodically.

Despite the usefulness of the mnemonic, I discontinued using it shortly after I began studying for my orthopedic boards. It wasn't that the method lost its effectiveness. It was because of a conversation I had with a medical radiologist who allowed me to read film with her as part of my studies. The second time I sat with her to read, I asked her if she used the ABC'S method or if she had another method. She replied, "The first thing I do is look for things that could kill 'em."

She said it in a joking manner, but she was absolutely serious. She then used the film we were looking at to give me an example. She proceeded to list everything that might be serious and/or lethal which could be seen on that particular series of film.



This had a profound effect on me and I began looking at all film in the same manner. Shortly after this, I revised the ABC'S mnemonic. Using my friend's example and an idea I had led to the mnemonic SCuBA. No, it does not stand for Self-Contained Underwater Breathing Apparatus. It stands for Soft tissue, Cartilage, unique findings, Bone and Alignment. [It was not tough coming up with the mnemonic. I simply reversed the ABC'S and then added the small "u." The "u" is lowercase because most of the unique findings are "Oh, by the way" in nature (see below for explanation).]

My thought process was related to the amount of attention given to the alignment portion of the ABC'S. I felt that alignment was stressed to such a degree in chiropractic that other aspects of the ABC'S could be underemphasized or ignored. I realized alignment had historically been the primary focus for most chiropractors, but this was changing significantly at the time.

I am talking here about the alignment noted for chiropractic technique listings; not gross misalignments that would cause abnormal atlantodental intervals, large breaks in George's line and similar findings. Line drawings associated with chiropractic techniques were falling into disfavor and malpractice against chiropractors for failure to diagnose or rendering the wrong diagnosis was increasing.

Many of the things that are serious or "could kill 'em" are seen in the soft tissues, cartilage and bone. Alignment usually won't "kill 'em," at least not those noted for technique. Fracture dislocations could, but those cases don't typically show up in our offices.

Swelling in the retropharyngeal or retrotracheal space on a lateral cervical view, increased heart size, a mass in the lung on an AP thoracic view, or an aortic aneurysm on a lateral lumbar view are not that uncommon. These are rather serious soft-tissue findings. A serious cartilage / joint finding that could be seen on a variety of film series is an infection of the intervertebral disc that has spread to the [vertebral bodies](#) of the adjacent vertebra.

Lung, breast, bowel, thyroid, prostate and kidney cancer have a predilection for metastasizing to the bones of the spine. Lytic and blastic destruction from these and primary cancers of bone can be seen in a variety of series. These are very serious findings. All of the above warrant closer looks prior to worrying about alignment and proceeding with care. I am not downplaying the significance of assessing alignment; I am stressing the significance of the other reading factors.

I think this subject is especially important when teaching the next generation of chiropractors. I had the opportunity to teach radiology at a chiropractic college a few years ago, and I discussed the ABC'S and the SCuBA mnemonic with students. Then I tested the students to see where their emphasis fell while reading film.

My test involved projecting a lateral cervical film on the classroom screen and asking the students to tell me what they saw. Almost without fail, most of the students would immediately describe the obvious loss of cervical lordosis seen on the film. They all noted the alignment first and then everything tapered off from that point.

If I did not respond to their answers and remained silent, they would realize there must be more to see and continue to stare at the film. Eventually, a few would see the bullet lodged in the vertebral body of C3. Occasionally, one would notice the small bone splinters near the chin. The bullet had nicked the chin and mandible on its way into the neck. (This phenomenon was seen less often as the students progressed in their studies.)

The unique findings or "u" placed in the middle of the reversed ABC'S is to remind the doctor (me) to look for those factors that make that patient / film unique. These could be artifacts, surgical clips, congenital deformities, medical devices and deliberate or accidental implants. Most of these findings are not as serious (things that "could kill 'em"), but they are still important.

Unique factors can range from "Oh, by the way" to "Wow" in importance. "Oh, by the way" findings could be things as benign as clothing artifacts, staples from a surgery reported during history, congenital abnormalities like spina bifida occulta or benign calcifications of tissues. "Wow" findings are often rare congenital abnormalities or possibly evidence of a major surgery not reported during history.

Isn't it amazing what the patients don't report during the history process? I once had a patient report a [gallbladder](#) removal and a hysterectomy as her only surgeries. Her lateral cervical film showed a bullet in her head. It also showed the holes drilled in her skull during the unsuccessful attempt to remove the bullet. She did not have functional brain impairment from the 22-year-old injury. It just seemed to have slipped her mind. I would think that if someone were asking me about my health history, and I had been shot in the head, it would be the first item on the list - if for no other reason than the fact I survived it.

The other reason the "u" was placed in the mnemonic is to have the mnemonic spell something, which is the whole point - to assist in remembering the mnemonic and its importance in the film-reading process.

I realize my mnemonic is not sanctioned by anyone but me. Nonetheless, I offer it as a tip from a practitioner with 25 years of experience in reading radiographs. Our chiropractic radiologists are our "go to" guys, but we all read film and we need to be good at it.

A final important note: Remember that there are always radiologists to help with reading film and you can always order additional tests if you have questions. The mnemonic I offer isn't perfect and it isn't a huge change from the ABC'S method, but it has helped me in practice and in teaching. I hope it helps you.

JULY 2012