

## Managing Sesamoid Injuries

Thomas Michaud, DC

The word *sesamoid* is Latin for "sesame seed." These small bones are located inside specific tendons, where they improve mechanical efficiency by pulling the tendon farther away from the joint's axis of motion. (Figure 1). The classic example of a sesamoid is [the patella](#), which improves mechanical efficiency of the quadriceps by more than 50 percent.<sup>1</sup>

The foot also possesses important sesamoids. Located beneath the first metatarsophalangeal joint, the tibial and fibular sesamoids (also known as the medial and lateral sesamoids) are situated in the tendon of the flexor hallucis brevis muscle, where they are separated by a small groove on the plantar surface of the metatarsal head. These small sesamoids are invaluable during the gait cycle, as they increase force production beneath the great toe during the propulsive period, which greatly improves stability.

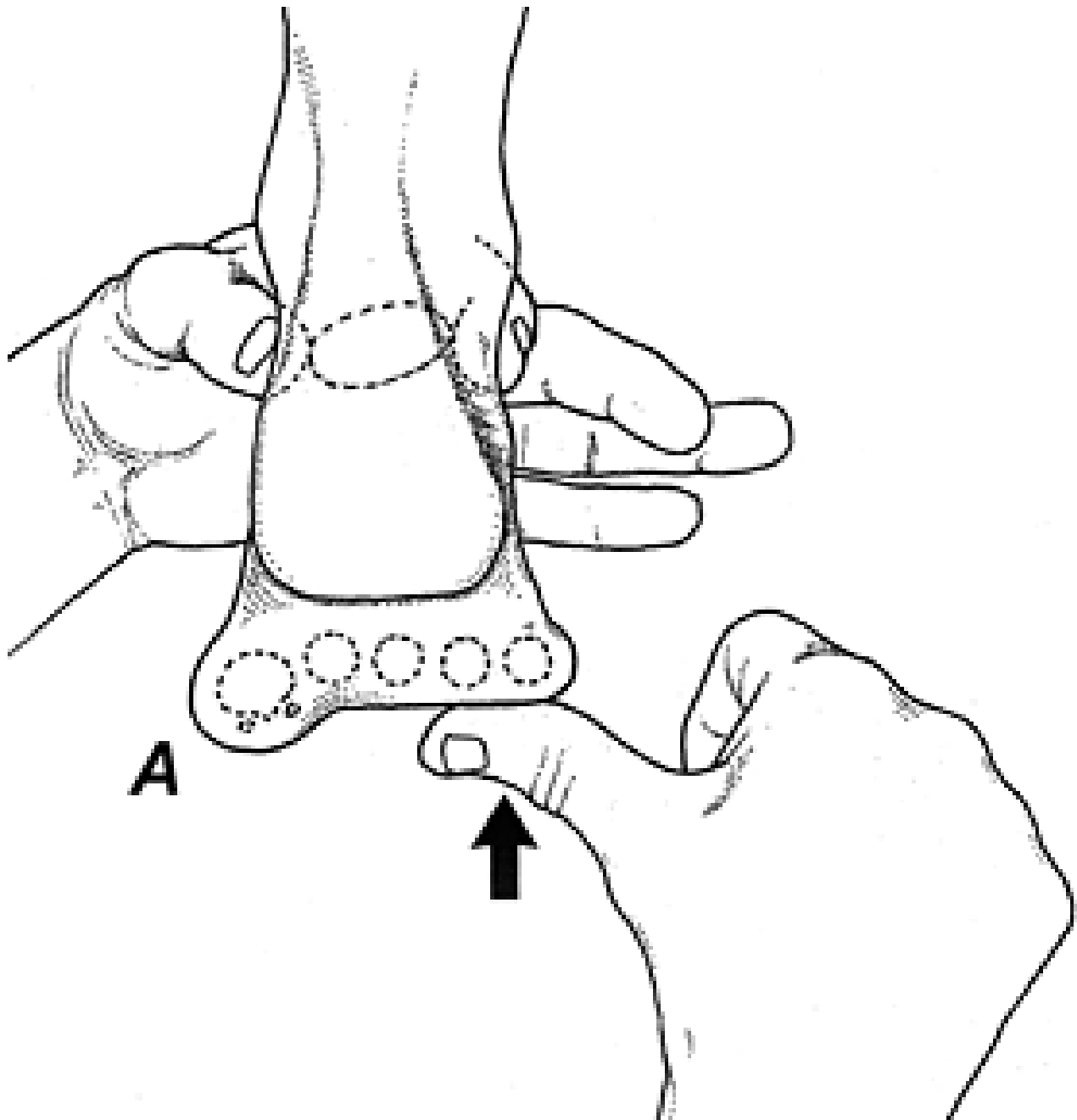


Fig. 2: With the foot in a neutral position, the plantarflexed first ray deformity is present when the first metatarsal is lower than the neighboring metatarsals (A).

By increasing the plantarflexory force generated beneath the hallux during the propulsive period, the sesamoids and flexor hallucis brevis play an important role in distributing pressure away from the central metatarsal heads onto the hallux. Ferris, et al.,<sup>2</sup> demonstrated that forceful hallux plantarflexion during propulsion reduces central metatarsal pressures by as much as 30 percent and may even play an important role in lessening the potential for metatarsal stress fractures.

Unfortunately, because they are located in a weight-bearing area, the sesamoid bones of the feet, unlike the patella, are subjected to tremendous compressive forces. The most common cause of a sesamoid injury is the rigid plantarflexed first ray. This alignment pattern is present in approximately 14 percent of the population and is extremely common in people with high arches. (Figure 2) Treatment in this situation is to reduce pressure by incorporating a sub-one balance. (Figure 3) This balance can be made in-office simply by taking a 1/8-inch-thick piece of felt and cutting out a J-shaped balance, which is then attached beneath the shoe or sneaker insole. Pre-

made sub-one balances can also be purchased and added to the shoe gear. (These balances are often referred to as dancer's pads.)

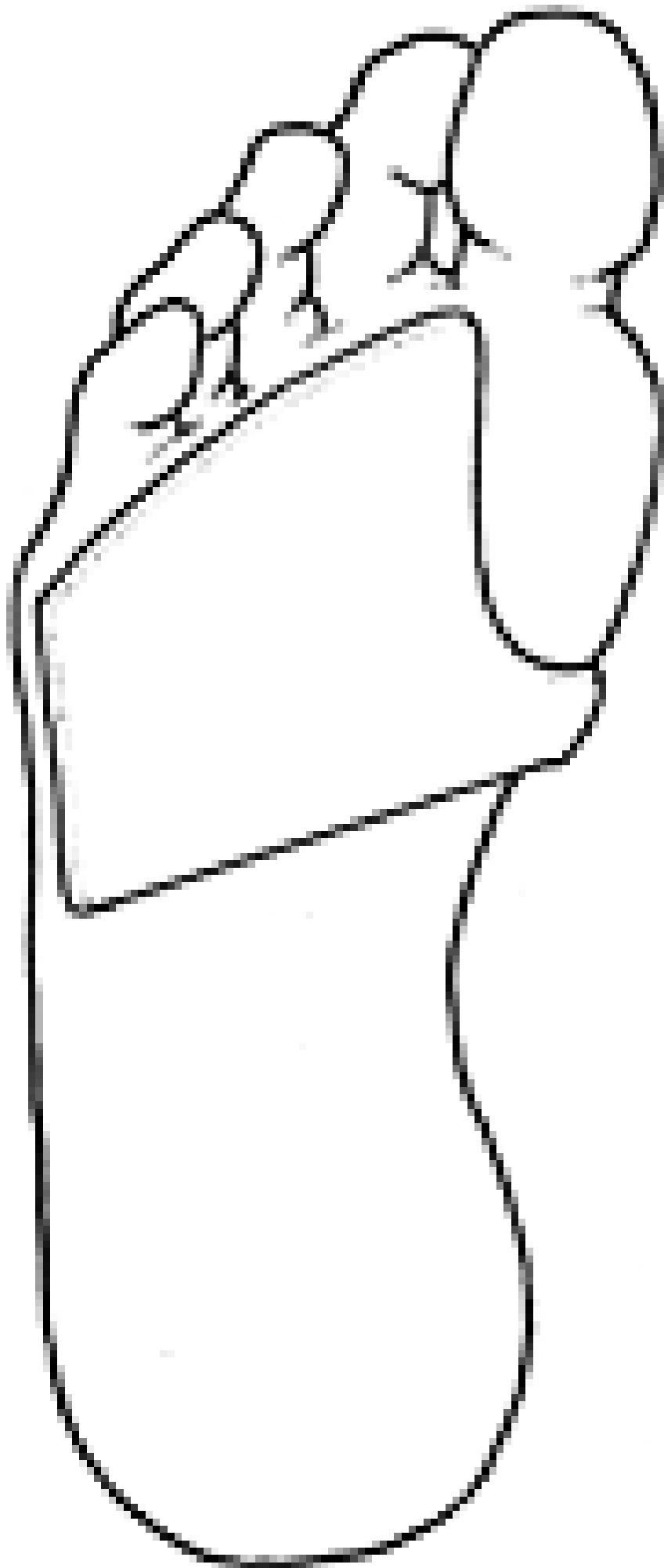


Fig. 3: The felt sub-one balance for lesion can be glued beneath an insole to lessen pressure beneath the first metatarsal head.

Excessive compression of the sesamoids, particularly the tibial sesamoid, also occurs in people with extremely **low arches**. This being the case, the excessive rearfoot eversion drives the medial forefoot into the ground with a greater force, eventually contusing the medial sesamoid. Effective treatment in this situation often requires prescribing an orthotic to distribute pressure away from the sesamoid onto the medial arch.

Regardless of the cause, the flexor hallucis brevis muscle often responds to chronic sesamoid injury by reflexively tightening. Increased tension in the flexor hallucis brevis often worsens the sesamoid injury, as it pulls the sesamoid into the plantar first metatarsal head when the hallux dorsiflexes during propulsion. A similar situation occurs in the knee when chronic retropatellar pain increases quadriceps tightness: The increased tightness of the quadriceps muscle displaces the patella into the femoral condyles when the knee flexes.

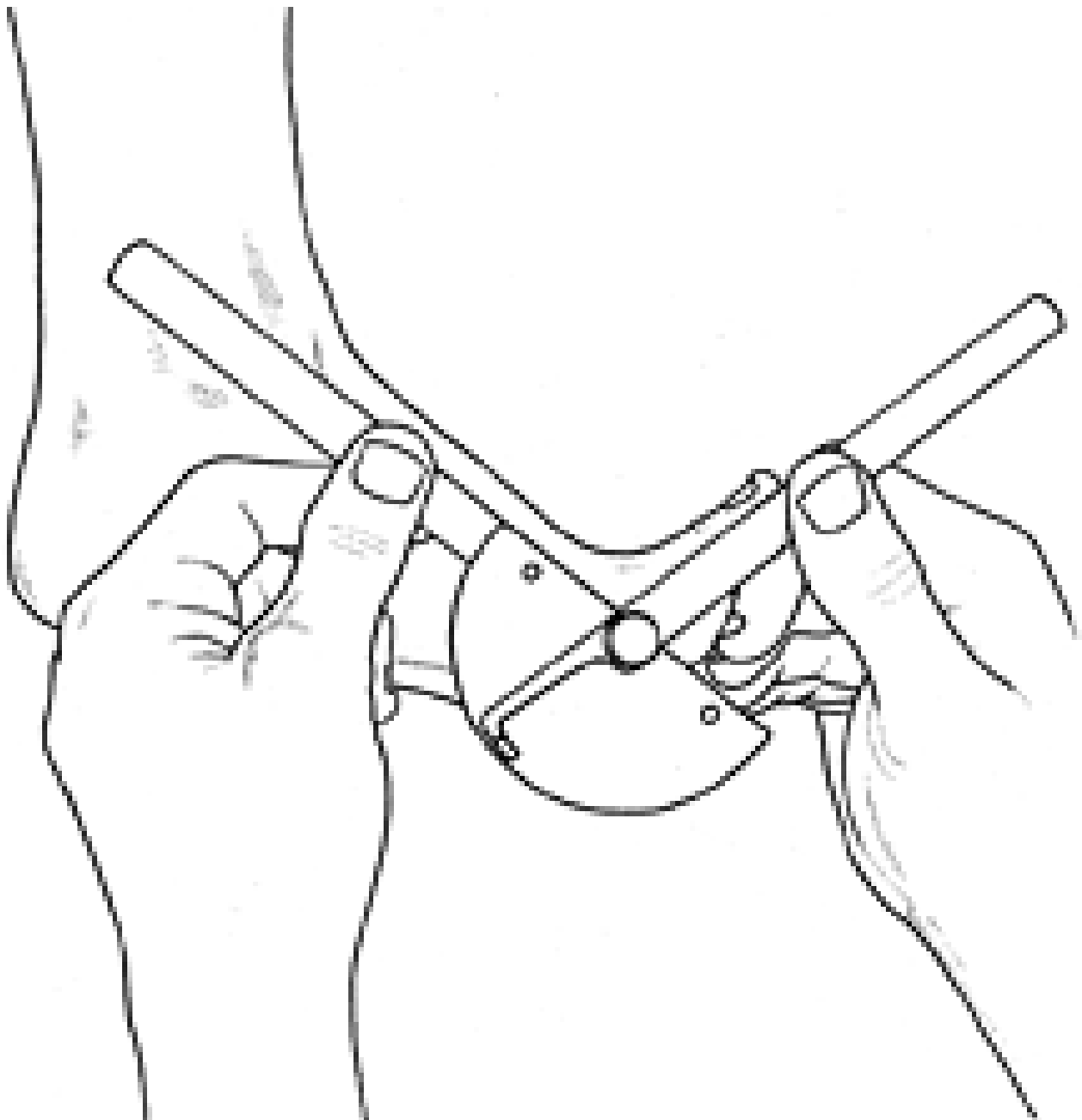


Fig. 4: Measuring hallux dorsiflexion with a goniometer.

In their two-year study of biomechanical factors responsible for the development of retropatellar pain, Witvrouw, et al.,<sup>3</sup> determined that quadriceps tightness was one of the best predictors of patellofemoral pain syndrome. In fact, quadriceps tightness played a more significant role in the development of retropatellar chronicity than a high Q angle and/or altered lower extremity alignment.

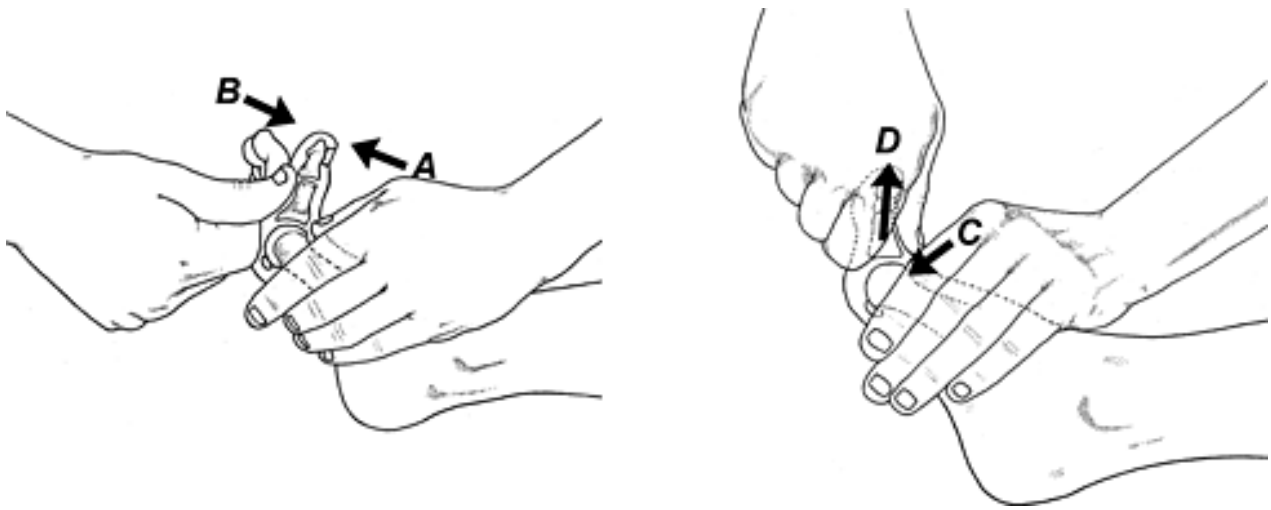


Fig. 5: Superior glide of the proximal phalanx on the first metatarsal head. Before performing this manipulation, the examiner performs deep-tissue massage along the entire flexor hallucis brevis muscle. This is followed with a series of hold-relax stretches in which the patient lightly presses against the examiner's thumb (A). Upon releasing the pressure, the examiner dorsiflexes the joint a few degrees, gently pushing the first metatarsophalangeal joint into a more dorsiflexed position (B). This process is repeated until bony resistance is noted. At this point, the examiner performs a series of gentle mobilizations in which the distal aspect of the first metatarsal head is driven inferiorly (C), while the proximal phalanx is tractioned (D). This treatment protocol is invaluable when treating chronic sesamoid injury.

While most chiropractors are aware that deep-tissue massage and quadriceps stretches are invaluable for the treatment of chronic retropatellar pain, few practitioners evaluate tension in the flexor hallucis brevis muscle when treating chronic sesamoid injury. The presence of flexor hallucis brevis contracture is easily confirmed by evaluating non-weight-bearing dorsiflexion of the first metatarsophalangeal joint. (Figure 4)

When an asymmetrical range is present, tension in the flexor hallucis brevis muscle may be reduced by performing deep-tissue massage over the entire length of the muscle, followed with a gentle muscle energy mobilization. Because first metatarsophalangeal joint dorsiflexion is associated with superior glide of the proximal phalanx on the metatarsal head, this mobilization is performed by coupling long-axis distraction, hallux dorsiflexion, and superior glide of the proximal phalanx on a metatarsal head. (Figure 5).

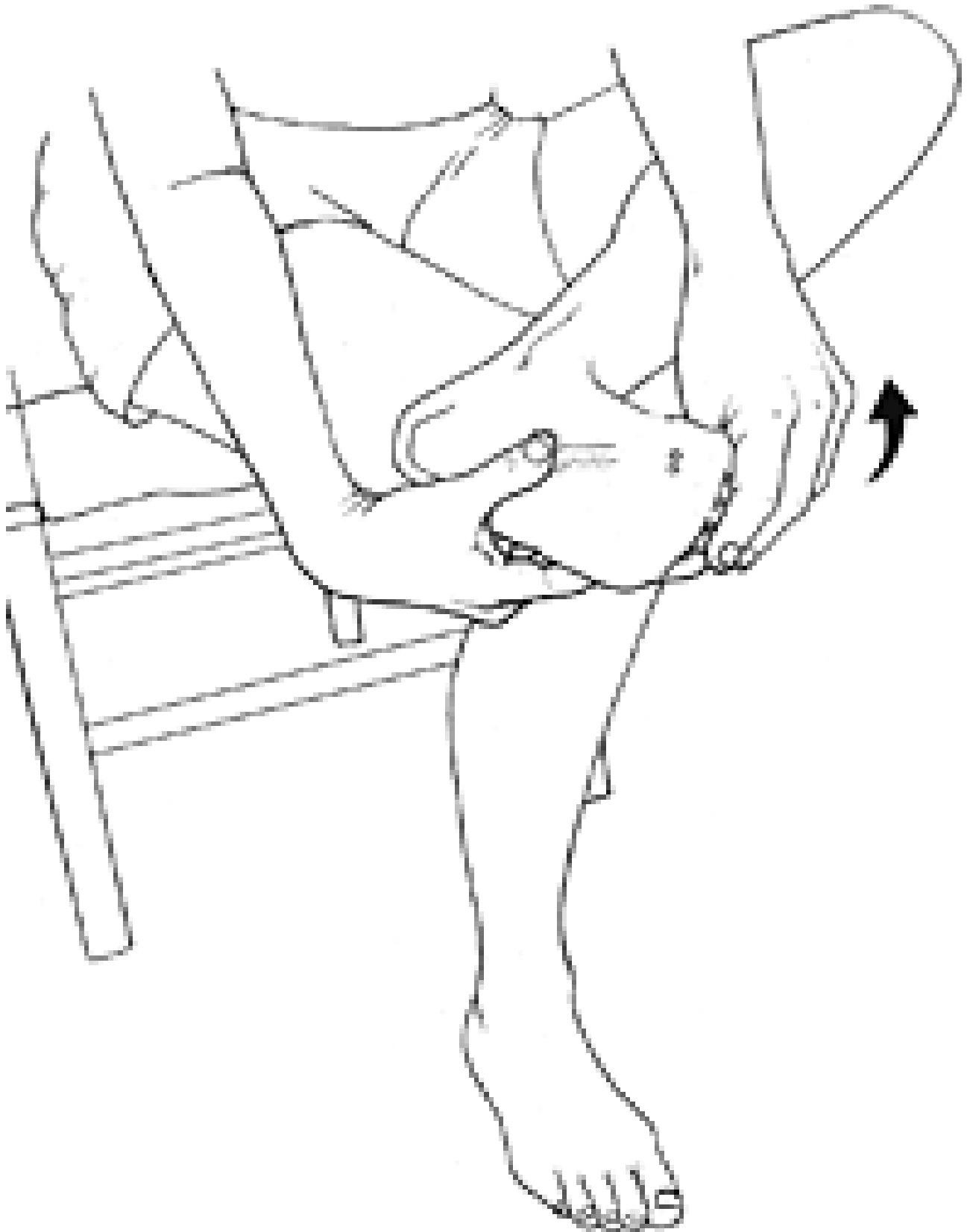

Fig. 6: Home stretch for the flexor hallucis brevis muscle. This stretch is maintained for 35 seconds and repeated 10 times/day.

When a tight flexor hallucis brevis muscle is responsible for limiting first metatarsophalangeal joint dorsiflexion, it is often possible to restore an additional 10 degrees of hallux dorsiflexion within a few minutes of performing this mobilization. (This is significant, since surgical release of the plantar fascia has been proven to restore only 10 degrees of first metatarsophalangeal joint dorsiflexion.)<sup>4</sup>



The patient almost always reports that the mobilization is comfortable; if it produces anything more than mild discomfort, the possibility of a sesamoid fracture and/or tendon injury should be considered and the appropriate diagnostic tests ordered. Home care is recommended and the patient is instructed to massage the flexor hallucis brevis muscle prior to performing the stretch illustrated in Figure 6. By incorporating in-office treatments and home mobilizations, full range of first metatarsophalangeal joint dorsiflexion can usually be restored within 4-6 weeks.

Just as the restoration of [quadriceps](#) flexibility is essential for comprehensive rehabilitation of retropatellar pain, improving flexibility of the flexor hallucis brevis muscle is essential when treating chronic sesamoid injury. By coupling manual therapy to restore motion with orthotic intervention to distribute pressure, even the most recalcitrant cases of sesamoid pain often have excellent outcomes.

### References

1. Fulkerson J. *Disorders of the Patellofemoral Joint, 3rd Edition*. Baltimore, MD: Williams & Wilkins, 1997.
2. Ferris L, Sharkey N, Smith T, et al. Influence of extrinsic plantar flexors on forefoot loading during heel rise. *Foot Ankle*, 1995;16:464-473.
3. Witvrouw E, Lysens R, Bellemans J, et al. Intrinsic risk factors for the development of anterior knee pain in an athletic population: a 2-year prospective study. *Am J Sports Med*, 2000;28:480.
4. Harton F, Weiskopf S, Goecker R. Sectioning the plantar fascia effect on first metatarsophalangeal joint motion. *J Am Podiatr Med Assoc*, 2002;92:532-536.

JANUARY 2012